

Review article

Open Approach in Rhinoplasty

Vjeran Bogović¹, Stjepan Grga Milanković¹, Željko Zubčić¹, Andrijana Včeva¹, Martina Mihalj², Josip Maleš¹, Željko Kotromanović¹, Mirjana Grebenar¹, Tihana Mendeš¹, Hrvoje Mihalj¹

¹ Department of Otorhinolaryngology, Head and Neck Surgery, Clinical Hospital Centre Osijek, Croatia

² Department of Physiology and Immunology, Faculty of Medicine, Osijek, Croatia

Corresponding author: Hrvoje Mihalj, mihalj.hrvoje@kbo.hr

Abstract

The aim of this study was to present the advantages and disadvantages of open approach in rhinoplasty. In it, we also present the development of this technique in Croatia and examine its application in the last five years at the Department of Otorhinolaryngology and Head and Neck Surgery of the Clinical Hospital Centre Osijek.

Retrospectively, from January 2008 to August 2012, 400 patients with septal deviation and/or deformities of the nasal pyramid who underwent open rhinoplasty at the Department of Otorhinolaryngology, Head and Neck Surgery of the Clinical Hospital Centre of Osijek, Croatia were identified. The clinical diagnosis was based on a detailed medical history of the patient and nasal endoscopy. The patients were photographed in six projections before and after the surgery, and followed up on two occasions.

(Bogović V, Milanković SG, Zubčić Ž, Včeva A, Mihalj M, Maleš J, Kotromanović Ž, Grebenar M, Mendeš T, Mihalj H. Open Approach in Rhinoplasty. SEEMEDJ 2019; 3(2); 56-62)

Received: May 24, 2019; revised version accepted: Sep 19, 2019; published: Dec 16, 2019

KEYWORDS: rhinoplasty, diagnosis, follow up

Introduction

Rhinoplasty is a procedure in plastic surgery of the nose which solves functional and aesthetic problems of nasal soft tissue. Rhinoplasty includes repositioning of nasal cartilage and bone as well as of soft tissue structures for the purpose of improving the function and aesthetic appearance of the nose (1). It is often necessary to do both rhinoplasty and septoplasty (surgery of the nasal septum which facilitates breathing) at the same time. Such combined surgery is called rhinoseptoplasty. Nasal deformities affect the aesthetics of the face, and rhinoplasty affects the individual functionally, aesthetically, artistically and psychologically. Rhinoplasty is one of the most complex and most challenging interventions in aesthetic surgery, where precision is down to a fraction of a millimetre. Anatomy of the nose is very complex, with challenging bone and cartilage structure, as well as variable thickness of the skin, with the thickest skin found on the apex. It is necessary to precisely determine how a certain procedure will affect the appearance of the nose (2).

History of medicine notes that the first successful aesthetic surgery of the nose was performed by the Brancas (father and son) in the 15th century, in the Italian province of Catania (3). At the beginning, rhinoplasty was considered to be a surgical part of psychotherapy, which is confirmed by the fact that at the start of the 20th century, depression was one of the indications for rhinoplasty. The father of modern techniques of rhinoplasty is Jacques Joseph, who lay the foundation of the surgical technique in 1928 (4). At the same time, in 1921, an otolaryngologist from Budapest named Aurel Rethy developed a new surgical technique, the so-called open approach or decortication. Rethy's technique was first modified by prof. Ante Šerčer, and his modified technique is still being applied all over the world today. Professor Ante Šerčer was born in Požega, completed his studies in Graz and Prague, and worked at the two biggest Clinical Hospital Centres (CHC) after World War II: "Šalata" (CHC Zagreb) and CHC Sestre

Milosrdnice. He is recognized as the greatest Croatian expert in otorhinolaryngology. His student, prof. Ivo Padovan, presented a new open approach technique (so-called decortication) in 1970 at the first international symposium of the American Academy of Facial Plastic and Reconstructive Surgery in New York, showing the results of the procedure conducted on 400 patients, who were operated at the Department of Otorhinolaryngology of the CHC "Sestre Milosrdnice" (5).

According to the claims of prof. Gunther, a famous American plastic surgeon, who is the organizer of one of the most popular international symposia for plastic and reconstructive head and neck surgery in Dallas, that method was not accepted in the USA until the 1970's. Today, a lot of ENT specialists and subspecialists of plastic and reconstructive head and neck surgery use decortication all over the world. As we can see from the available data, 98% of patients are operated on by surgeons using this approach at the Clinical Hospital in Dallas. The respected prof. Toriumi from Chicago uses the open approach for more than 85% of all rhinoplasty procedures. In the USA, surgeons perform over 100 000 aesthetic rhinoplasties annually (6).

The nose is located at the centre of the face; it is also the most protruding part of the face, which is why it is the most exposed part of the face for trauma. It can be changed as a result of trauma, genetic factors or disease. Nasal trauma is the most common cause of aesthetic deformities of the septum and of the external part of the nose. Aesthetic nose correction is the most challenging surgery in aesthetic surgery. The spectrum of deformities of the external part of nose is varied and because of that, the approach and planning of surgical procedure must be done on a case-by-case basis. Typical nose deformities include: dorsal hump, saddle nose, crooked nose, overprojected nose, wide nose and combinations of the above. The goal of rhinoplasty is to create the nose shape that would best fit the face, because every face is different, and the nose needs to be adjusted

accordingly. Rhinoplasty may be primary (correction for the first time) or secondary (reoperation). There are two main approaches to rhinoplasty: intranasal and open (decortication). Deformities may be located in the bone and/or cartilage. In the open approach, a small incision is performed on the columella and along the front edge of alar cartilage, and in that way, deformities may be corrected. Open approach is indicated in severe deformity of the apex, or for noses that have been operated multiple times or have suffered trauma multiple times, since they cannot be operated on using the intranasal approach. In the open approach, a small scar is left in the shape of the letter V at the columella (the fleshy part that divides the nostrils). Skin haematoma of the apex lasts

longer than when the intranasal technique is used, which depends mostly on the type of skin on the apex. Breathing normally through the nose should never be sacrificed to achieve the desired aesthetic nose shape (7).

Patients and methods

This retrospective analysis was made at the Department of Otorhinolaryngology and Head and Neck Surgery of the Clinical Hospital Centre Osijek.

A total of 400 patients with functional and/or aesthetic nose surgeries performed in the period from January 2008 to August 2012 were included (Table 1).

Table 1. Functional and aesthetic rhinoplasty performed at the Department of Otorhinolaryngology and Head and Neck Surgery of the Clinical Hospital Centre Osijek from 2008 to 2012.

Type of surgery	2008	2009	2010	2011	8/2012	Total
Septoplasty	44	56	57	67	55	279
Rhynoseptoplasty (open and intranasal approach)	12	17	18	32	21	100 (28, 72)
Reconstruction of nasal valve	0	4	8	5	4	21
Total						400

Study design

Before surgery, after taking the patient's anamnesis, the patient was photographed and

analysed from six different angles. Attention was drawn to the nasolabial angle, which is 90-110 degrees in women, and 80 to 90 degrees in men, while the nasofrontal angle is generally about 150 degrees in both sexes (Figure 1).

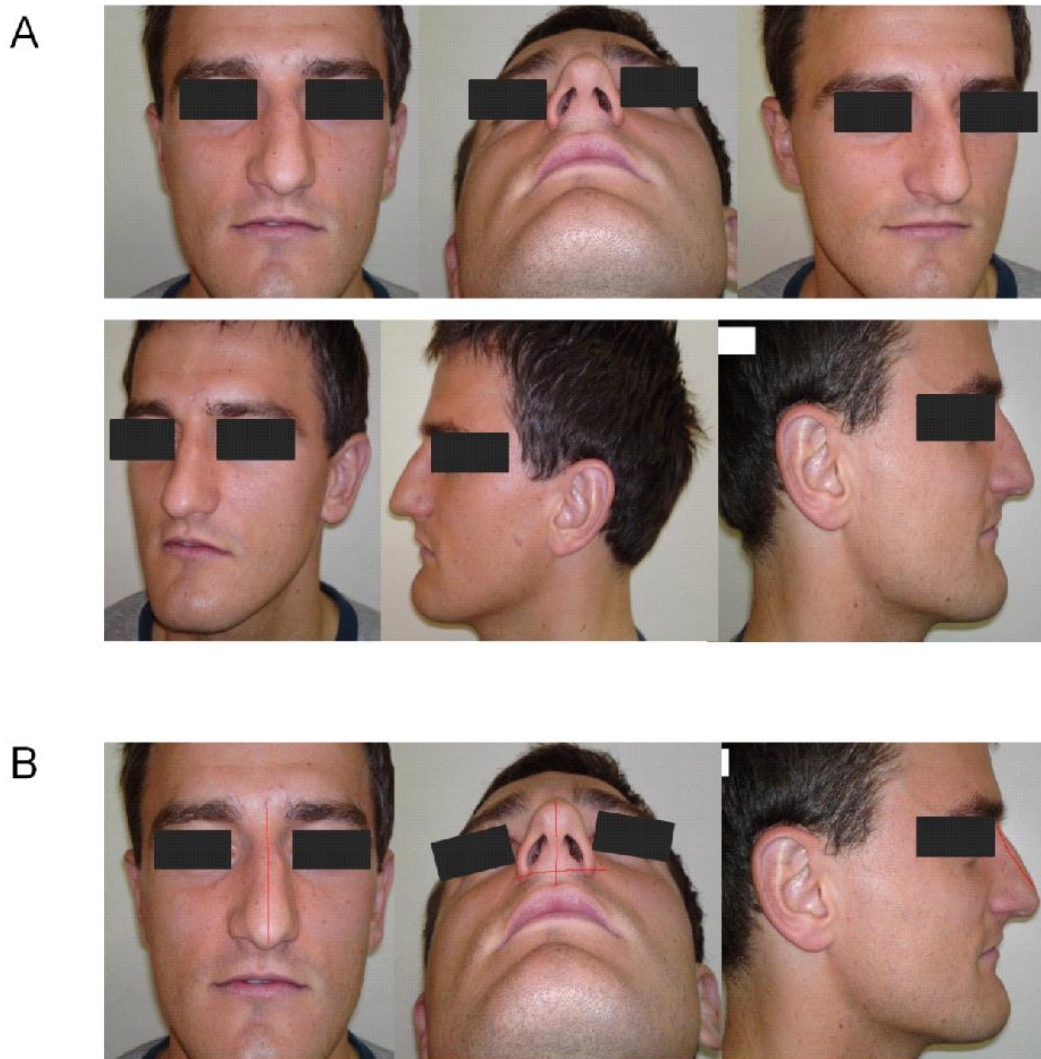


Figure 1. Preoperative photo

After thorough anamnesis was taken, the preoperative patient was photographed and analysed from six different angles (Figure 1A) (5). Attention is drawn to the nasolabial angle, which is 90-110 degrees in women, and 80 to 90 degrees in men, while the nasofrontal angle is generally about 150 degrees in both sexes. Figure 1B shows deviations from the median plane and clearance of the nose and preoperative planning of the operation.

Functional and/or aesthetic nose surgeries performed were septoplasty, rhinoseptoplasty (open or intranasal approach) and reconstruction of the nasal valve. After the surgery was

completed, the results were monitored and documented by repeated photographing from the same six angles (Figure 2).

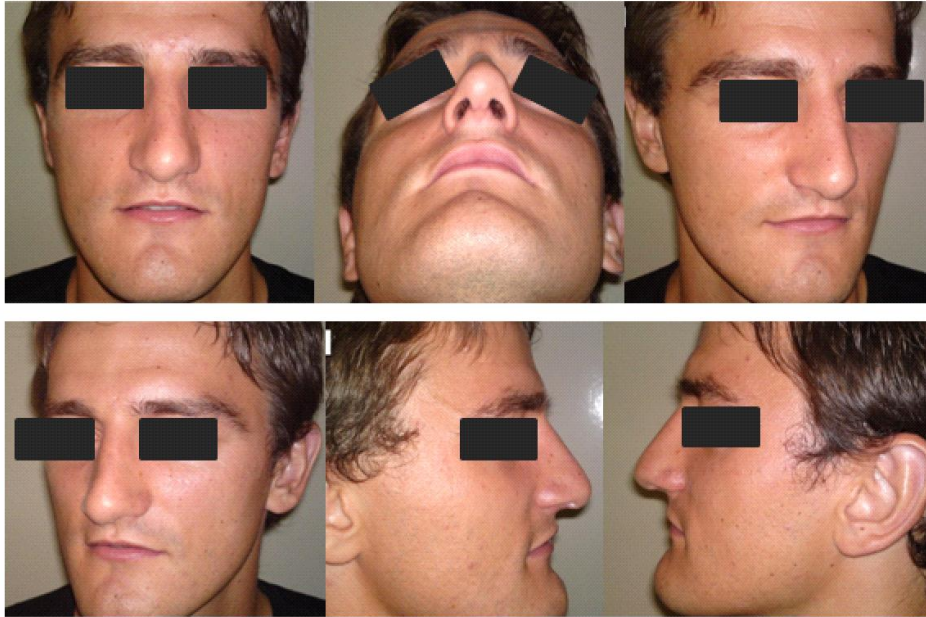

Figure 2. Postoperative photo

The results of the operation are monitored and documented by repeated photographing from six angles. Figure 2 shows the same patient after rhinoseptoplasty was performed; the increase in the nasolabial angle is noticeable, as is the corrected nasal dorsum.

Results

We noted 279 septoplasties, 100 rhinoseptoplasties and 21 reconstructions of the nasal valve (Table 1). From the presented data, it is evident that the number of surgical interventions at the annual level is constantly increasing, which is in line with the increase in the number of ENT surgeons employed at our hospital, who were educated at other hospitals in Croatia, as well as in world-renowned centres for plastic reconstructive surgery.

Discussion

In addition to the functional dimension, the nose has an essential aesthetic dimension. In functional terms, the nose is the initial and extremely important part of the respiratory system. Apart from the "air conditioning" the inhaled air, the nose also contains nerve endings that are responsible for distinguishing odours (5).

Generally, the appearance, i.e. the anatomic material, reflects the function of the breathing dynamics. It is therefore clear that any plastic surgery performed on the nose is also a functional surgery. Along with the aforementioned "technical" aspect, the appearance of the nose is affected by race, ethnic characteristics and individual heritage. Within each race, there are typical characteristics. In the black race, for example, the nose is wider than the nose in the white race; it is lower in the bony part, with a predominance of wide noses, and the columella is shorter, with horizontal nostrils. In the white race, we differentiate the Greek, the Latin, the Galician, the Germanic nose, etc. (8). Finally, the appearance of the nose can be affected by the surgeon. It is not unusual that, apart from correcting individual characteristics, members of individual races or ethnic groups want to re-shape the basic characteristics of their nose; for example, in Asia, people tend to strive to "westernize" by changing the East Asian elements of their physiognomy.

Southeastern European Medical Journal, 2019; 3(2)

Surgery requires four fundamental criteria – three objective and one subjective: balanced form, good function, correct proportions, and desired appearance. The common notion that the nose changes the profile is only partially correct because rhinoplasty affects the shape of all projections. If the surgery meets the objective requirements, the surgeon may be satisfied, but for complete success, the patient must also be satisfied. Therefore, it is necessary that the surgeon, prior to performing the surgery, has an interview with the patient to find out which anatomical specifics the patient is not satisfied with and what the patient's particular aesthetic expectations are regarding the appearance of the nose. This is important because patients sometimes have unrealistic expectations of surgery or motivations that are not in fact related to the appearance of the nose, but are caused by other social and psychological circumstances that they project on their external appearance (9).

Complications of rhinoplasty are relatively rare (10). Possible complications include: nosebleeds, swelling of the nose and the surrounding soft tissue of the eyes and cheeks (especially in "open" rhinoplasty, lasting up to one year), bleeding, infections, hypertrophic scars, re-deformation of the nose (due to scars and poor surgical techniques). Some patients can develop difficulty breathing through the nose following rhinoplasty, despite a successful aesthetic outcome of the operation. Even though the inside of the nose generally allows for good passage of air, rhinometric measurement of the airflow should measure the nasal discharge insufficiency. This is damage to the fine mechanism responsible for normal airflow in the throat and normal discharge, and it may be congenital or acquired. Treatment of this condition is very difficult and unpredictable, so it is best if it is prevented by proper surgical technique. Decisions regarding nose surgery should be preceded by detailed discussion and review of the situation. On that occasion, the doctor explains the nature of the problem to the patient and the realistic possibility of its correction. After rhinoplasty, a patch, plaster splint or plastic material is used to keep the

shape and position of the nose for the first 7-10 days until it is healed. Nose and face swelling is individual, depending on the severity of the surgery itself and the response of the patient's tissue. A return to daily activities is possible after approximately two weeks, depending on the individual situation. Strenuous physical activity should be avoided over the next two months. It is important to understand that the recovery process after rhinoplasty takes from six months to a year, until the nose reaches its final appearance. The final judgment on the appearance and function of the nose is made by the patient and the surgeon only after five years of patient monitoring, which is particularly the case in the West (10). Bleeding after the removal of the tampon is the most commonly observed complication; it is usually weak and stops after a few minutes. In some cases, the tampon is replaced until the next day. Sweating is not a common complication. The nose has very good blood supply, which provides a strong immune defence against pathogens, and today's medical institutions also follow stringent protocols regarding sterilization and instrument handling. Unsatisfactory aesthetic effect of the surgery is considered to be one of the late-stage complications of rhinoplasty (11). In some cases, the result of the surgery differs from what the patient expected, and this usually occurs when the desired look does not match the result achieved. To prevent this, realistically expected results are discussed prior to surgery, as well as after surgery. When images before and after the surgery are compared to help patients see the improvement in their appearance, most patients are satisfied.

Repetitive rhinoplasty, also known as secondary rhinoplasty (12), is rhinoplasty performed to correct inadequate results of the previous rhinoplasty. There are two reasons for performing secondary rhinoplasty. Patients often seek secondary rhinoplasty to correct a cosmetic nasal deformity. Nose fracture may not have been sufficiently reduced or was done too low (13). The overprojected nose may not be adequately resolved, or it may have been overly resolved. It may look squashed; it may look like a bell pepper or like a boxer's nose. There are

many ways in which the results of the previous rhinoplasty can be aesthetically unattractive to the patient. Another reason is the functionality. In the first case, rhinoplasty may be done to alleviate breathing difficulties, and the result may be unsatisfactory. In the second case, the first rhinoplasty may be performed for cosmetic reasons, but may also endanger the normal physiological mechanism that involves inhaling or exhaling, making it difficult to breathe. Secondary rhinoplasty is technically challenging

References

1. Rohrich R, Ahmad J. Rhinoplasty. *Plast Reconstr Surg* 2011; 128(2):49-73.
 2. Vilar-Sancho B. Rhinoseptoplasty. *Aesthetic Plast Surg* 1984; 8(2):61-65.
 3. Greco M, Ciriaco AG, Vonella M, Vitagliano T. The primacy of the Vianeo family in the invention of nasal reconstruction technique. *Ann Plast Surg* 2010; 64:702-5.
 4. Bhattacharya S. Jacques Joseph: Father of modern aesthetic surgery. *Indian J Plast Surg*. 2008;41(suppl): S3-S8.
 5. Šercer A. *Otorinolaringologija 2, Klinika*. Zagreb: JLZ, 1965, 356-357.
 6. Gunter JP, Rohrich RJ, Adams, WP (Eds.). *Dallas Rhinoplasty - Nasal Surgery by the Masters*, 2nd edn., St. Louis: Quality Medical Publishing Inc; 2007
 7. Šercer A, Mundich K. *Plastische Operationen an der nase und an der Ohrmuschel*, Stuttgart: Georg thieme verlag, 1962
 8. Leong S, Eccles R. A systematic review of the nasal index and the significance of the shape and size of the nose in rhinology. *Clin Otolaryngol* 2009; 34(3):191-8. doi: 10.1111/j.1749-4486.2009.01905.x.
 9. Naraghi M, Atari M. Development and Validation of the Expectations of Aesthetic Rhinoplasty Scale. *Arch Plastic Surgery* 2016; 43(4):365-370.
 10. Cochran CS, Landecker A. Prevention and management of rhinoplasty complications. *Plast Reconstr Surg* 2008; 122:60-67.
 11. Rettinger G. Risks and complications in rhinoplasty. *GMS Curr Top Otorhinolaryngol Head Neck Surg*. 2007;6:Doc08.
 12. Gruber RP, Noland S, Belek KA. Discussion: what motivates secondary rhinoplasty? A study of 150 consecutive patients. *Plast Reconstr Surg* 2012; 130:679-80.
 13. Philpott CM, Clark A, McKiernan DC. Function or cosmesis--what is the predominant concern in patients with nasal trauma presenting for rhinoplasty? *Eplasty* 2009;9:e11.
- Daniel R. Secondary Rhinoplasty Following Open Rhinoplasty. *Plast Reconstr Surg* 1995; 96(7):1539-1546.