

Vocal Cord Paralysis and Parathyroid Cyst

Davorin Đanić¹, Ljubica Fuštar Preradović², Rajko Jović³, Ana Đanić Hadžibegović¹

¹ Department of Ear, Nose and Throat, Head and Neck Surgery, "Dr Josip Benčević" General Hospital, Slavonski Brod;

Department of Ear, Nose and Throat and Maxillofacial Surgery, Osijek School of Medicine, Josip Juraj Strossmayer University in Osijek, Osijek, Croatia

² Pathology and Cytology Laboratory, Dr Josip Benčević General Hospital, Slavonski Brod, Croatia

³ Clinical Department of Ear, Nose and Throat, Cinical Center Vojvodina, Novi Sad, Serbia

Corresponding author: Assist. Prof. Ana Đanić Hadžibegović, MD, PhD - ana_djanic@yahoo.com

Abstract

Aim: Parathyroid gland lesions are an extremely rare clinical entity, mostly manifesting as adenoma and hyperplasia, rarely as parathyroid cysts, and most infrequently as carcinoma. Parathyroid cysts are frequently asymptomatic lesions of the neck and the superior mediastinum with only 300 cases reported in the literature. Symptomatic parathyroid cysts are very rare. Vocal cord paralysis due to recurrent laryngeal nerve dysfunction may herald the presence of neck and mediastinal disease including a variety of neoplastic, inflammatory and vascular conditions. The aim of this report is to describe their clinical presentation, diagnostic procedures, and therapeutic approaches. The objective of the study was to assess the presence of vocal cord paralysis and recurrent laryngeal nerve dysfunction, as well as their association in patients with recurrent laryngeal nerve.

Methods. We performed a 12-year departmental review of parathyroid lesions and parathyroid cysts. Retrospective analysis of clinical data on 20630 unselected patients submitted to thyroid gland and neck ultrasonography yielded 149 (0.007%) patients with parathyroid lesions, six (0.0003%) of them with parathyroid cysts. A comprehensive review of the literature revealed 18 patients with vocal cord paralysis and parathyroid cysts.

Results: Parathyroid adenoma were present in 97/149 (0.65%) and hyperplasia in 46/149 (0.30%) patients with parathyroid lesions. Parathyroid cysts were present only in six of 149 (0.04%) patients with parathyroid lesions. Five patients had asymptomatic nonfunctional parathyroid cysts, with vocal cord paralysis diagnosed in one female patient. In the 19 patients with parathyroid cysts and vocal cord paralysis reported in the literature (including the patient reported here), nine and ten patients had parathyroid cysts localized in the neck and mediastinum, respectively. Mediastinal cysts were twofold greater than those localized on the neck, while left recurrent laryngeal nerve dysfunction was recorded in 80% of cases. Cyst removal resulted in recurrent laryngeal nerve functional recovery in two-thirds of patients.

Received: April 27, 2017; revised version accepted: May 25, 2017; published: May 26, 2017

KEYWORDS: Parathyroid lesion; Cyst; Vocal cord; Paralysis; Cytology

Conclusion: Parathyroid cysts are rare, mostly asymptomatic pathologic lesions of parathyroid glands that should be taken into consideration in patients with hyperparathyroidism or vocal cord paresis.

(Đanić D, Fuštar Preradović Lj., Jović R, Đanić Hadžibegović A. Vocal Cord Paralysis and Parathyroid Cyst, SEEMEDJ 2017;1(1):136-143)

Introduction

Parathyroid glands and their lesions are present in four different histopathologic and clinical entities, mostly as adenoma and hyperplasia, and rarely as cysts or carcinoma. Parathyroid cysts (PTCs) are an uncommon cause of VCP. PTCs are benign neck tumors and that account for 0.8%-3.41% of all parathyroid lesions (1, 2). The true prevalence of PTC remains uncertain, and more than 300 patients with cystic lesions of parathyroid glands have been reported in the literature. About 200 of these lesions were localized in the neck, and the rest occurred in the mediastinum (2, 3). PTCs mostly occur at the age of 40-50 with a female predominance (female to male ratio, 2.5:1) and a few cases in pediatric patients. Generally, the left side of the neck and inferior parathyroid glands are involved. True PTCs, found in 80% of patients, are nonfunctional and asymptomatic. Occasionally, depending on their size and localization, PTCs may cause dysphagia, pain, and tracheal compression or RLN lesion (2, 3). Functional PTCs that develop by parathyroid adenoma cystic degeneration are found in 20% of patients (3). These PTCs usually occur as solitary lesions, whereas multiple functional PTCs are extremely rare and are associated with hyperparathyroidism (2, 3, 4, 5). Only one case of malignant PTC transformation has been described in the literature (6).

The etiology of vocal cord paralysis (VCP) is very heterogeneous and the true incidence of VCP in the general population is hard to estimate. According to Shafkat et al., 42 cases per 10 000 new patients can be expected at ENT clinic (7). Most frequently, VCP develops as a sequel of recurrent laryngeal nerve (RLN) dysfunction caused by a malignant tumor, various inflammatory processes or vascular

malformations. A malignant tumor localized in the neck or mediastinum leads to RLN dysfunction by its aggressive growth, pressure or traction, and most frequently by nerve infiltration. Damage to RLN is considerably less commonly induced by benign tumors of the neck. The incidence of rare and idiopathic VCP varies from 16.3% to 31.1% (8, 9).

Current diagnostic tools including ultrasonography, multi-slice computed tomography (MSCT), magnetic resonance imaging (MRI) and technetium-99m sestamibi scanning can often differentiate solid tumors from cystic lesions. However, differentiating a thyroid cyst from PTC is challenging. Ultrasound-guided fine needle aspiration cytology (US-FNAC) is a useful test to confirm the diagnosis in case of clinically suspected parathyroid glands and parathyroid lesions, but also to detect a parathyroid gland of an unexpected localization, e.g., in the thyroid bed or within the thyroid gland. A parathyroid lesion may present as thyroid incidentaloma, a lesion incidentally found within or adjacent to the thyroid gland (10) (Fig. 1). The aim of the present study was to evaluate the clinical characteristics, diagnostic difficulty and our experience in therapy of PTCs.

Material and Methods

Study design: A retrospective analysis was performed on a cohort of 20 630 patients who submitted to ultrasonography examination of the thyroid gland and neck. Thyroid gland and neck ultrasonography reports were reviewed for diameter and the location of the suspect parathyroid lesions. Ultrasound-guided fine needle aspiration cytology (US-FNAC) of the parathyroid gland was performed under continuous, ultrasound visualization with use of

Table 1. Clinical and laboratory characteristics of parathyroid cyst patients (N=6)

| Patient No. | Initials, age (yrs)/gender | Symptoms | Localization | Cyst size | Serum PTH pg/mL | Cyst PTH pg/mL | Therapy: FNA/Surgery |
|-------------|----------------------------|---|----------------|-----------|-----------------|----------------|----------------------|
| 1 | 51/F | Osteodynia | Left inferior | 21 mm | 35.43 | 240.1 | FNA |
| 2 | 76/F | Hoarseness Left vocal cord paresis | Left inferior | 22 mm | 30.31 | 389.5 | Surgery |
| 3 | 54/F | Dry cough Nonspecific breathlessness at exertion | Left inferior | 24 mm | 29.22 | 498.0 | Surgery |
| 4 | 44/F | Left-sided hemithyroidectomy | Right inferior | 17 mm | 64.3 | 21 770 | FNA |
| 5 | 50/M | Nephrolithiasis | Left superior | 45 mm | 77.61 | 103.1 | FNA |
| 6 | 79/M | Nonspecific swallowing disturbance | Right inferior | 18 mm | 110.90 | 337.0 | Surgery |

PTH = parathyroid hormone; FNA = fine needle aspiration

an ACUSION X 300 device using 8.9 MHz and 11 MHz probes. The medical records were reviewed for clinical symptoms, biochemical measurements, ultrasonography reports, cytology data, surgical treatments and pathology reports.

Statistical Analysis

Proportions were expressed as percentages, whereas all continuous variables were calculated as median and range. There were no inter- or intra-group comparisons needing further statistical analyses.

Results

The analysis yielded 149 patients with parathyroid lesions out of 20630 examinations (0.007%), including 97 (65.1%) patients with parathyroid adenoma, 46 (30.8%) patients with hyperplasia and six (4.0%) patients with PTCs. There were four female and two male PTC patients with a median age of 52.5 (minimum 44, maximum 79, range 35) years and a median cyst size 21.5 mm (minimum 17, maximum 45, range 28 mm) (Table 1).

These six patients with PTCs underwent US-FNAC, and the presence of parathyroid hormone (PTH) was confirmed by aspirate biochemistry on a Cobas e411 analyzer (Roche, Mannheim, Germany). Nonfunctional PTCs were present in five patients and VCP in one patient. One patient had a functional PTC, with a parathyroid hormone (PTH) level of 77.61 pg/mL and normal serum and ionized calcium levels. The surgical extirpation of the cysts and histopathologic analysis were performed in three patients, whereas the other three patients underwent US-FNAC (Fig. 2 and 3). The study protocol was approved by the Hospital Ethics Committee and by the Zagreb School of Medicine Ethics Committee.

A comprehensive review of the literature from 1953 to the present showed 19 patients with PTC and VCP, including our patient reported herewith (Table 2). There were 53% males, with a median age of 54 (minimum 29, maximum 83, range 54) years, and a median cyst size of 48 mm (minimum 12, maximum 123, range 111 mm). Ten PTCs were localized in the mediastinum and nine in the neck; there were 16 nonfunctional PTCs. Functional PTCs were present in three female patients, accompanied by elevated serum PTH and calcium levels. Left-sided VCPs

Table 2. Reported 19 cases of VCP associated with benign parathyroid cysts

| Reference | Public. date | First author | Age/ Gender | Local. | Size mm | Functional cyst status | Neck side | Treatment | Postop. status |
|-----------|--------------|--------------|----------------|--------|------------|---------------------------|--------------|-----------|-------------------|
| 11. | 1953. | Crile G. Jr | 69/F | M | 60 | NF | R | S | N |
| 8. | 1966. | Hayashi S. | 48/M | M | 83 | NF | R | S | N |
| 12. | 1978. | Clark O.H. | 29/F | M | 63 | NF | L | S | N |
| 13. | 1983. | Marco V. | 42/M | M | 12 | NF | L | S | N |
| 14. | 1988. | Takahashi E. | 68/F | M | 73 | F | R | S | N |
| 15. | 1990. | Delauny T. | 71/F | M | 40 | F | L | S | N |
| 16. | 1991. | Coates G. | 60/M | N | 80 | NF | L | A | P |
| 8. | 1992. | Narita Y. | 54/M | M | 123 | NF | L | S | N |
| 17. | 1993. | Grey A.B. | 38/F | N | 20 | NF | L | A | N |
| 18. | 1997. | Landau O. | 77/M | M | 88 | NF | R | S | P |
| 19. | 2000. | Sen P. | 37/F | N | 25 | NF | L | A | N |
| 20. | 2006. | Coelho D.H. | 49/M | N | 48 | NF | R | S | N |
| 21. | 2006. | Sihoe A.D. | 51/M | M | 95 | NF | L | S | N |
| 22. | 2008. | Woo E.K. | 83/M | N | 39 | NF | L | S | P |
| 23. | 2011. | Ghervian C. | 50/F | N | 42 | NF | L | A | N |
| 24. | 2012. | Khan A. | 58/F | N | 32 | F | R | S | P |
| 25. | 2013. | Menezes VC | 56/M | M | 72 | NF | L | S | N |
| 26. | 2015. | Arduec A. | 30/M | N | 30 | NF | L | S | N |
| | 2016. | Danic D. | 76/F | N | 22 | NF | L | S | P |

N- neck; M-mediastinum; F- functional; NF- nonfunctional, S- surgery; A- aspiration; P- paralysis RLN; N- normal functional status RLN

were found in 15 patients. In 80% of patients, PTCs were surgically removed in toto, whereas 20% of patients underwent transcutaneous aspiration of the cyst content. In two-thirds of patients, PTC removal resulted in functional RLN recovery.

Discussion

Parathyroid lesions are rare clinical entities, and parathyroid cysts are uncommon forms of parathyroid lesions, possibly even referred to as 'a forgotten diagnosis' (27). Microcysts of the parathyroid gland are a common occurrence in the normal population and are found primarily in aging glands along with increased fat content. Macroscopic cysts of the parathyroid glands that

are larger than 10 mm in diameter are referred to as parathyroid cysts and necessitate investigation. The clinical presentation is very different; functional parathyroid cysts are relatively easier to detect than nonfunctional ones. PTCs are diagnosed by clinical symptoms and biochemical parameters of hyperparathyroidism with elevated serum calcium levels, and postoperatively by histopathology demonstrating parathyroid gland tissue in the cyst wall and the postoperative correction of the PTH level and hypercalcemia (3). Generally nonfunctional parathyroid cysts are asymptomatic and incidentally diagnosed during clinical work-up for thyroid disorders or other neck and chest soft tissue tumors (10, 27).

Southeastern European Medical Journal, Vol 1, 2017.

Figure 1. Thyroid ultrasound showing cystic mass adjacent to the left lobe of the thyroid gland

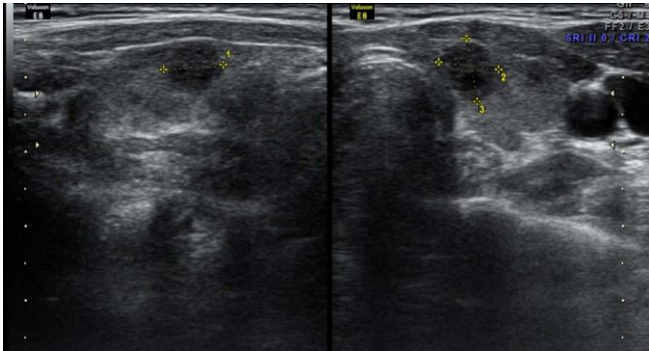


Figure 2. Thyroid preparation with adjacent cystic of a parathyroid gland (own source)

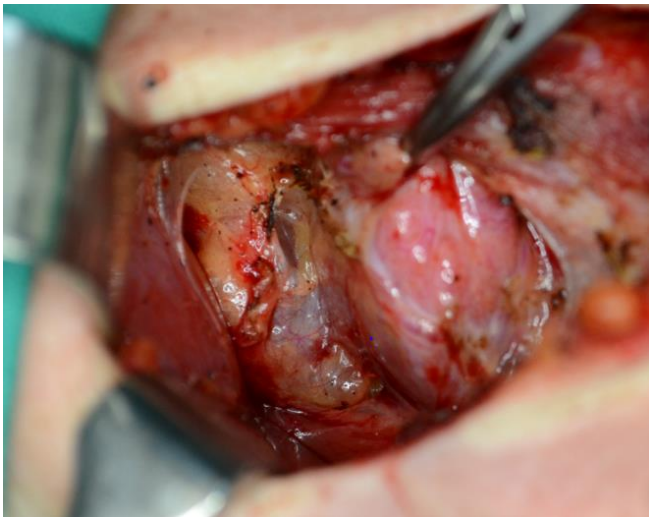
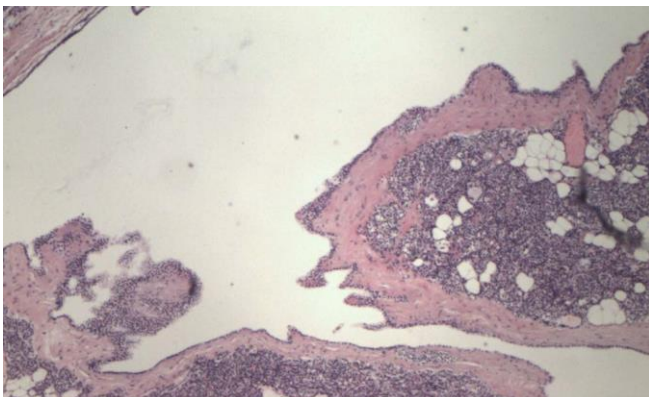


Figure 3. Parathyroid gland histology (own source)



Histopathology: inner cyst surface lined with a layer of flat epithelial cells; parathyroid gland tissue along the cyst connective wall (hemalaun-eozin stain)

Vocal cord paresis can be caused by recurrent laryngeal nerve lesions of various etiologies. Surgical traumas and tumors are most commonly involved, though the cause remains

unknown in one-third of lesions. The rare causes of VCP include cardiovascular syndromes, cervical spine osteophytes, tracheal diverticula, subclavian artery aneurysm, jugular vein thrombosis, and meningomyelocele (g). PTC has been described in several studies as a rare cause of VCP. Ho and McMullen report on 13 patients with various parathyroid gland lesions considered to have caused VCP. Functional PTCs were present in six patients, four of them with the clinical picture of hyperparathyroidism and a histopathology report indicating adenoma, and two patients with secondary hyperparathyroidism and a histopathology report indicating hyperplasia. Three patients had both PTCs and parathyroid gland nonfunctional hyperplasia, whereas five patients had true nonfunctional PTCs, two of them suffering from VCP and clinically present tumor mass on the neck, and one patient complaining of pain in the neck (27). PTCs belong to a group of extremely rare causes of VCP. In their study that included 93 patients with mediastinal PTCs, Shields and Immerman recorded nine (9.5%) patients with VCP. True nonfunctional PTCs were found in seven patients and functional PTCs in two female patients (5). In our unselected cohort of 20 630 patients that underwent neck and thyroid gland US, parathyroid lesions were recorded in 147 (0.007%) patients and PTCs in only six (0.0003%) patients, with VCP found in only one female patient (Table 1).

That patient was a 76-year-old female presented for clinical ENT examination due to hoarseness persisting for months. Fiberoscopy, laryngostroboscopy and electromyography studies revealed left-sided VCP. Standard biochemistry parameters showed no pathologic findings. The patient underwent neck and thyroid US examination (Figure 1). Based on these findings, the diagnosis of nonfunctional PTC was made. She underwent a minimally invasive surgical procedure. The cyst was surgically extirpated in toto, while saving RLN carefully (Figure 2). Follow up biochemistry parameters obtained 24 h postoperatively were within reference range. Histologic examination confirmed the presence of PTC (Figure 3). At 12 months after the surgery, the patient had left-

sided VCP and dysphonia, without breathing and swallowing difficulties. Serum levels of PTH, calcium and phosphorus were within the reference range.

About 300 patients with PTCs have been reported in the literature to date, 200 of these localized in the neck and 100 in the mediastinum (1, 5, 27). Analysis of the available literature yielded 19 patients with PTC and VCP, including our patient reported herewith (Table 2). The number of patients with neck and mediastinal PTCs was almost equal, i.e., nine and ten, respectively. A review of the present literature shows the prevalence of VCP was twofold greater (10 %) in patients with the PTC localized in the mediastinum than in those with the PTC in the neck (4.5 %). This finding may be due to the twofold greater median cyst diameter (75.5 mm) and probably a higher compression of the cyst wall upon RLN in patients with mediastinal PTCs as compared with the median neck cyst size of 37.5 mm. In our patients, the median PTC size was significantly lower, i.e., 24.6 mm. In 80% of patients, PTCs were localized on the left side of the neck or mediastinum with left-sided VCP. Left RLN is known to be more vulnerable than right RLN because of its length and localization. In two-thirds of patients, PTC removal resulted in the functional recovery of RLN. A review of the present 19 patients according to the functional cyst status shows that 16 patients had asymptomatic PTCs and three female patients had functional PTCs.

Loss of RLN function can be caused by a variety of mechanisms. In some patients, loss of RLN function can be explained by the known and verified pathologic mechanisms. A large cystic growth exerts nerve compression and/or traction, while local inflammation or edema can lead to neurapraxia and eventually to axonotmesis with a loss of function. In patients with long-standing renal insufficiency, the loss of RLN function can occur as a sequel of a hemorrhage into the PTC, frequently associated with inflammation (27). Major intracystic hemorrhages and RLN lesions were found in patients with hypercalcemic episodes and functional PTCs (24). In the majority of these patients, nerve and VCP recovery ensued after

PTC removal. In malignant tumors, of the thyroid gland in particular, nerve lesions can be induced by direct invasion of malignant cells or by nerve compression by nodular hyperplasia in the case of a benign growth. However, in some cases, the cause of the loss of RLN function remains obscure, as in our patient. Accordingly, in some PTC patients, the loss of RLN function and VCP appear to occur due to some other unidentified cause, or VCP and PTC are present concurrently but without mutual interaction.

The modality and extent of PTC treatment is determined by its size, localization, functional status, and cyst-related complications. Minimally, invasive surgery for PTC removal is the gold standard in the treatment of functional PTCs. In patients with true nonfunctional PTCs and symptoms of adjacent organ compression, we believe that surgical removal of the cystic lesion is necessary, along with relieving the neck or mediastinum structure compression, with special attention paid to RLN. Percutaneous cyst aspiration is a satisfactory therapeutic procedure in small, asymptomatic, nonfunctional and uncomplicated cysts (27). In patients with permanent VCP, speech therapy, augmentation injections, or unilateral medialization laryngoplasty should be used. In our patient, three months of speech therapy resulted in satisfactory voice quality.

There were several limitations of our study. The most important ones were retrospective design, a single center experience, and a small number of cases that did not allow any statistical analyses.

In conclusion, our study has demonstrated that parathyroid cysts are rarely encountered in general neck and mediastinum pathology, but should not be forgotten as a possible cause of unilateral VCP. Functional and larger PTCs are easier to diagnose than small and asymptomatic ones. US-FNAC and aspirate biochemistry for PTH are the standard diagnostic procedures for this entity. Minimally invasive surgery with in toto cyst extirpation is the gold standard in the treatment of all cystic lesions associated with complications.

Funding:

No specific was received for this study.

Competing interests:

None to declare.

References

1. Pontikides N, Karras S, Kaprara A, Cheva A, Doumas A, Bostsios D, oschidis A, Efthimiou E, Wass J, Krassas G. Diagnostic and therapeutic review of cystic parathyroid lesions. *Hormones* 2012;11(4):410-8.
2. da Silva DA, Machado MC, Brito LL, Guimaraes RA, Fava AS, Mamone MCAC. Parathyroid cysts: diagnosis and treatment. *Rev Bras Otorhinolaringol* 2004;70 (6):840-4.
3. Wirowski D, Wicke C, Bohner H, Lammers BJ, Pohl P, Schwarz K, Goretzki PE. Presentation of 6 cases with parathyroid cysts and discussion of the literature. *Exp Clin Endocrinol Diabetes* 2008;116(8):501-6.
4. Entwistle JW, Pierce CV, Johnson DE, O'Donovan SC, Bagwell CE, Salzberg AM. Parathyroid cysts: report of the sixth and youngest pediatric case. *J Pediatr Surg* 1994;29:1528-9.
5. Shields TW, Immerman SC. Mediastinal parathyroid cysts revisited. *Ann Thorac Surg* 1999;67:581-90.
6. Vazquez FJ, Aparicio LS, Gallo CG, Diehl M. Parathyroid carcinoma presenting as a gigant mediastinal retrotracheal functional cyst. *Singapore Med J* 2007;48:e 304.
7. Shafkat A, Muzamil A, Lateef M. A study of incidence and etiopathology of vocal cord paralysis. *Indian J Otolaryngol Head Neck Surg* 2000;54:30-2.
8. Kay-Rivers E, Mitmaker E, Payne RJ, Hier MP, Mlynarek AM, Young J, Forest VI. Preoperative vocal cord paralysis and its association with malignant thyroid disease and other pathological features. *J Otolaryngol Head Neck Surg* 2015;44:35.
9. Sobrino-Guijarro B, Virk JS, Singh A, Lingam RK. Uncommon and rare causes of vocal fold paralysis detected via imaging. *J Laryngol Otol* 2013;127:691-8.
10. Fuštar-Preradović Lj, Šarčević B, Đanić D. Morphometry in differential diagnosis of pathologically altered parathyroid glands: adenoma and hyperplasia. *Coll Antropol* 2012;36:47-1.
11. Crile G Jr, Perryman RG. Parathyroid cysts. Report of five cases. *Surgery* 1953;14:151-4.
12. Clark OH. Parathyroid cysts. *Am J Surg* 1978;135:395-402.
13. Marco V, Carrasco MA, Marco C, Bauza A. Cytomorphology of a mediastinal parathyroid cyst. Report of a case mimicking malignancy. *Acta Cytol* 1983;27:688-92.
14. Takahashi E, Kohno A, Narimatsu A, Miyake H, Kimura F, Shigeta A, Itaoka T, Wada Y. A case of mediastinal parathyroid cyst. *Jpn J Clin Radiol* 1988;33:393-6.
15. Delaunay T, Peillon C, Manourvrièr JL, Deotto JF, Doucet J, Nicaise JM, Watelet J, Testart J. Cysts of the parathyroid glands. Apropos of 6 cases *Ann Chir* 1990;44:231-5.
16. Coates G, Pearman K, Holl-Allen RTJ. Recurrent nerve palsy duo to parathyroid cyst. *Int Surg* 1991;76:192-3.
17. Grey AB, Shaw JH, Anderson NE, Holdaway IM. Parathyroid cyst with recurrent vocal cord paresis. *Aust N Z J Surg* 1993;63:561-2.
18. Landau O, Chamberlain DW, Kennedy RS, Pearson FG, Keshavjee S. Mediastinal parathyroid cysts. *Ann Thorac Surg* 1997;63:951-3.
19. Sen P, Flower N, Papesch M, Davis A, Spedding AV. A benign parathyroid cyst presenting with hoarse voice. *J Laryngol Otol* 2000;114:147-8.
20. Coelho DH, Boey HP. Benign parathyroid cyst causing vocal cord paralysis: a case report and review of the literature. *Head Neck* 2006;28:564-6.
21. Sihoe AD, Chir B, Cheng LC, Sit AK. Mediastinal parathyroid cyst: a rare benign cause of voice hoarseness. *Chest* 2006; 130 (4_Meeting Abstracts).347B-b
22. Woo EK, Simo B, Conn B, Connor SEJ. Vocal cord paralysis secondary to a benign parathyroid cyst: a case report with clinical, imaging and pathological findings. *Eur Radiol* 2008;18:2015-8.

23. Ghervan C, Goel P. Parathyroid cyst, a rare cause of cystic cervical lesion. Case report. *Med Ultrason* 2011;13:157-60.
24. Khan A, Khan Y, Raza S, Akbar G, Khan M, Diwan N, Rizvi W. Functional parathyroid cyst: a rare cause of malignant hypercalcemia with primary hyperparathyroidism – a case report and review of literature. *Case Rep Med* 2012;2012: 851941.
25. Menezes VC, Cardoso PFG, Minamoto H, Jacomelli M, Gutierrez PS, Jatene FB. Mediastinal cyst as a cause of severe compression and dysphonia. *J Bras Pneumol* 2013;39: 636-40.
26. Arduc A, Tutuncu Y, Dogan BA. Parathyroid cyst. *Am Surg* 2015;81:163-5.
27. Fuštar Preradović Lj, Đanić D, Džodić R. Small nonfunctional parathyroid cysts: single institution experience. *Endocrine J* 2017;64(2):151-56.
28. Ho TWT, McMullen TP. Secondary hyperparathyroidism presenting with vocal cord paralysis. *World J Endocrine Surg* 2011;3(3):122-4..