

## The Correlation of Ultrasonographic and Pathophysiologic Measurements of Umbilical Vessels in Gestational Diabetes

Mária Jakó<sup>1</sup>, Andrea Surányi<sup>1</sup>, László Kaizer<sup>2</sup>, Dóra Domokos<sup>3</sup>, György Bártfai<sup>1</sup>

<sup>1</sup> Department of Obstetrics and Gynecology, University of Szeged, Szeged, Hungary

<sup>2</sup> Department of Pathology, University of Szeged, Szeged, Hungary

<sup>3</sup> Department of Pharmacodynamics and Biopharmacy, University of Szeged, Szeged, Hungary

Corresponding author: Mária Jakó MD, PhD fellow - jmarica8@gmail.com

### Abstract

**Aim:** The resistance of placental blood vessels might be increased in diabetic pregnancies. This increased resistance can affect uteroplacental blood flow and influence the oxygen and nutrient supply of the fetus and fetal growth. Our aim was to compare the ultrasonographic, pathomorphologic data and vasoreactivity of umbilical and placental vessels of gestational diabetic newborns with that of normal pregnancy newborns.

**Methods:** In this case-control study the placental vascularization of pregnant women was determined by 3D power Doppler ultrasound technique. We calculated the vascularization index (VI), flow index (FI) and vascularization flow index (VFI). We performed a tissue bath experiment (treatment with oxytocin and desmopressin) on umbilical vessels and collected pathomorphologic data according to the Royal College of Pathologists' 2011 protocol.

**Results:** The placental vascularization index and the umbilical artery S/D were significantly lower in the case group. The mean VI was 6.21% ( $\pm 2.69$  SD) in control versus 3.5% ( $\pm 2.97$  SD) ( $p < 0.05$ ) in GDM. The mean value of the umbilical artery S/D was 2.27 ( $\pm 0.22$  SD) and 2.18 ( $\pm 0.45$  SD) ( $p < 0.05$ ) respectively. In an isolated tissue bath experiment, oxytocin and desmopressin did not elicit significant contraction on umbilical cord vessels.

**Conclusion:** Our results suggest that umbilical vessels might have a different receptor pathway regulation that can compensate for the rheological changes in the pregnant woman's blood flow and gives opportunity for selective therapy to fetuses more vulnerable to hypoxia.

(Jakó M, Surányi A, Kaizer L, Domokos D, Bártfai G. The Correlation of Ultrasonographic and Pathophysiologic Measurements of Umbilical Vessels in Gestational Diabetes. SEEMEDJ 2017;1(1):40-49)

Received: March 7, 2017; revised version accepted: April 20, 2017; published: April 24, 2017

KEYWORDS: Gestational Diabetes, 3D Power Doppler, Histopathology, Umbilical cord

## Introduction

Gestational diabetes mellitus (GDM) affects 14% of pregnancies, or 135,000 women a year in the USA, although its incidence varies nationwide. The mother's risk for conversion to type 2 diabetes ranges from 2.6 to 70% over a period from 6 weeks to 28 years postpartum (1). There are many, noncorresponding data regarding the prevalence of GDM in Hungary. In a population-based screening program, 75 g OGTTs were offered to all pregnant women between 24–28 weeks of gestation and evaluated according to WHO criteria. In that study 8.7% of pregnant women were diagnosed with GDM, and the risk increased linearly with maternal age. Women with the highest BMI ( $\geq 29.2$  kg/m<sup>2</sup>) had decreased risk compared to women with a BMI of 26.1–29.1 kg/m<sup>2</sup> ( $p < 0.05$ ). These results suggest that pre-pregnancy BMI and previous deliveries elevate the risk of GDM only to a certain level, above which the risk decreases (2).

Postprandial glucose concentrations steadily increase as tissue sensitivity to insulin decreases. To maintain proper blood glucose value along pregnancy, the pancreatic gland of the mother increases insulin secretion to compensate. Insulin resistance and impaired insulin secretion by the pancreas cause the development of GDM, especially during the third trimester of pregnancy (3). Pregnancy is a complex metabolic state that involves dramatic alterations in the hormonal milieu, changes in adipokines and inflammatory cytokines. There are high levels of estrogen, progesterone, prolactin, cortisol, human chorionic gonadotropin, placental growth hormone, human placental lactogen, leptin, TNF $\alpha$ , and oxidative stress biomarkers. In addition, decreases in adiponectin worsen maternal insulin resistance in the second trimester (4). The placental and fetal demands for glucose are considerable and approach the equivalent of ~150 grams per day of glucose in the third trimester. Glucose transport to the fetus occurs in direct proportion to maternal glucose levels, and is augmented by a five-fold increase in a

placental glucose transporter, (GLUT-1) which increases transplacental glucose flux (5). Fetuses exposed to a high glucose environment usually have medical complications after delivery, including infant respiratory distress syndrome, cardiomyopathy, hypoglycemia, hypocalcemia, hypomagnesaemia, polycythemia, and hyperviscosity. The hyperglycemia and adverse pregnancy outcome (HAPO) study, which investigated about 25,000 pregnant women in 15 centers, found that even in subclinical hyperglycemia, higher maternal BMI was associated (odds ratio [95% confidence interval] with an increased frequency of birthweight >90th percentile (3.52 [2.48–5.00]) and percentage of body fat >90th percentile (3.28 [2.28–4.71]), caesarean section (2.23 [1.66–2.99]), and cord C-peptide >90th percentile (2.33 [1.58–3.43]) (6). The first line of management of women with gestational diabetes is medical nutrition therapy and a given minimum of exercise. Patients who fail to maintain normal glycemic values via diet and exercise therapy receive insulin (7).

As umbilical cord vessels represent a suitable model for the study of vascular alterations brought about by GDM, the aim of the present work was to compare the ultrasonographic vascular flow measurements to pathological microvascular changes, and also to test the vasoreactivity of the vessels. The chosen agents were oxytocin, which is present naturally at the time of pregnancy and can pass through the placenta (8), and vasopressin, an oxytocin receptor agonist. Oxytocin and vasopressin are both peptide hormones, and oxytocin is widely used to promote labor contractions in clinical practice. The effects of these peptides are mediated via transmembrane receptors. Both the oxytocin receptor (OTR) and the V1a vasopressin receptor (V1aR) are expressed in human myometrium. The expression of OTR is significantly higher in gravid uterus while V1aR expression is not significantly elevated compared to non-gravid uterus (9). Oxytocin gene and receptor expression have also been shown in human chorion, deciduas and amnion

epithelial cells with the onset of labor. The structural similarity of the two peptides (approximately 80%), as well as the homology of the receptors, causes some cross-reactivity between peptides and receptors (10). The placental presence of V1aR mRNA is known in sheep but not in humans. The lack of AVP mRNA suggests the fetal origin of the ligand (11). Pharmacological studies suggest the existence of vascular endothelial AVP/OT receptors that mediate a vasodilatory effect. However, the nature of the receptor subtype(s) involved in this vasodilatory response remains controversial. RT-PCR experiments with total RNA extracted from a human umbilical vein endothel amplified the OT receptor sequence only, but various vascular beds display different sensitivities to AVP (12). Other studies suggest that the vasopressin receptor type 2 is responsible for vasodilation via nitrogen-monoxide production (13,14). To the best of our knowledge, no receptor subtypes have been investigated in umbilical arteries, and the fetal production of the ligands is a hypothesis.

We hypothesize that during myometrial contraction the above mentioned vascular relaxation can maintain fetoplacental circulation. The aim of this study was to investigate whether the vasodilatory effect of AVP/OT receptor pathways is present in fetoplacental circulation. We also wanted to investigate whether the diabetic vasculopathy and vessel calcification affects this vasodilation.

## Materials and Methods

### *Ultrasound screening*

We collected samples of umbilical cords from the Department of Obstetrics and Gynecology at the University of Szeged from October, 2013 until June, 2014. Focusing on the well-known risk factors, a detailed medical history was taken, and relying on the results of routine ultrasound screening, fetal biometry and anamnesis, we set up a case group of gestational diabetic pregnancies (GDM fetuses) (n = 5) and compared them to a control group (n = 22).

Gestational diabetes was diagnosed at gestational weeks 24-28 as hyperglycemia, first detected in pregnancies that met the WHO's guide criteria (15). Each of the patients with gestational diabetes was treated with dietary restrictions and monitoring. No insulin treated patients were included. The control group consisted of patients without diabetes or other endocrinologic, vascular or pulmonary disease. They delivered normal weight, healthy newborns. Those who did not fit any of the above criteria were excluded from this study.

Gestational age was determined based on the first day of the last menstrual period and on ultrasound biometry (crown-rump length [CRL] and biparietal diameter [BPD]) at the 10th week of pregnancy. All patients were scanned in a semirecumbent position. The factorial default setting "Obstetrics/2-3 trimester" was used in 2-D mode. The examination was followed by a fetal biometry to assess BPD, head circumference (HC), abdominal circumference (AC) and femur length (FL). Fetal weight was calculated by the formula B of Hadlock (16). A conventional color Doppler study of umbilical arteries was also performed and the systolic velocity/diastolic velocity (S/D) ratio, the resistance index (RI) and pulsatility index (PI) were read from the ultrasound report display.

The images used for the determination of placental volume and three-dimensional power Doppler (3DPD) indices were obtained at the time of the visit. All 3-D scans and the 2-D ultrasound measurements were performed. Voluson 730 Expert ultrasound machines equipped with a multifrequency probe (2-5 MHz) were used to acquire all images (GE Medical Systems, Kretztechnik GmbH&Co OHG, Austria). Each sample was examined using a 3-D rendering mode, in which the color and gray value information was processed and combined to produce 3-D images (mode cent; smooth: 4/5; FRQ: low; quality: 16; density: 6; enhance: 16; balance: 150; filter: 2; actual power: 2 dB; pulse repetition frequency: 0.9). A power Doppler window (pulse repetition frequency at 900 Hz and wall filter of 50 Hz) was placed over the placenta mapping the vascular tree from the basal to chorionic plates. We used fast low

resolution acquisition to avoid any kind of artifact. The 3-D static volume box was placed over the highest villous vascular density zone at umbilical cord insertion (17-19). During gestation we recorded one sample from each patient. The stored volumes were further analyzed using the Virtual Organ Computer-aided Analysis (VOCAL) program pertaining to the computer software 4D View (GE Medical Systems, Austria, version 10.4) by an expert in 3-D analysis (18). The power Doppler technique shows high sensitivity, because it is based on amplitude instead of mean frequencies to depict the vascular tree (19). Moreover, the color mapping is independent from the angle of insonation and does not show "aliasing". The placental vascular indices from sonobiopsy are a valid alternative for evaluation of the placental vascular tree when visualization of the entire placenta is not feasible. Based on the ultrasonographic technique vascularization index (VI, the perfusion of the tissue, the percentage of blood flowing through), the flow index (FI, the amount of red blood cells flowing through a given area in a given time) and their combination, the vascularization flow index (VFI) can be determined (20). The spherical sample volume was consistently 28ml. The VOCAL program calculated automatically gray and color scale values in a histogram from the acquired spherical sample volume in each case (18-19).

The delivery mode and duration with gestational age were recorded in the delivery room along with the body weight and body length of the newborn, of which Röhner's ponderal index could be calculated with a normal value between 2.2 and 2.9. For statistical reasons, the gender and 1-5 minute Apgar-scores were also registered.

#### *Tissue Bath Study*

At the placental insertion two 10 cm long segments of the umbilical cord were removed immediately and the one proximal to the placenta was stored at 4°C, in pH 7.4 Krebs-Henseleit solution (118 mM NaCl; 4.7 mM KCl; 1.2 mM KH<sub>2</sub>PO<sub>4</sub>; 1.2 mM MgSO<sub>4</sub>·7H<sub>2</sub>O; 2.5 mM CaCl<sub>2</sub>·2H<sub>2</sub>O; 25 mM NaHCO<sub>3</sub>, 11.7 mM dextrose).

The samples were processed and stored in an ice-lined stainless steel thermos, and the solution was freshly prepared on a weekly basis and stored in a refrigerator until used. The vessels were dissected from Wharton's jelly within 24 hours to maintain their reactivity (11). The arteries were cut into two 3-5 mm long rings, and 4 similar rings were prepared from the vein. They were suspended on stainless steel hooks and placed in a tissue bath containing a Krebs-Henseleit solution at 37°C, exposed to 2g initial tension and bubbled with carbogen (95% O<sub>2</sub>, 5% CO<sub>2</sub>). During the sixty-minute equilibration time we washed the system throughout with fresh solution every 15 minutes and let the spontaneous basal tone of the vessels to develop. Oxytocin and desmopressin were added to the vessels in the concentration range of 10<sup>-9</sup>-1x10<sup>-5</sup>M and 10<sup>-11</sup>-10<sup>-7</sup>M, respectively. The change in the vascular tone was detected by isometric sensors and recorded and analyzed by ISOSYS S.P.E.L. advanced computer software (Experimetria Ltd, Budapest, Hungary). The results are interpreted as the percentage of the basal, spontaneous vascular tone represented as 100% in value. The functionality of the vessel rings was tested with serotonin, which caused vasoconstriction, proving the viability of the vessels.

#### **Pathological Examination**

The placenta, along with the other segment of the cord, was stored in formalin for the morphological and histological examinations. The macroscopic evaluation of the samples followed the protocol published in 2011 by the Royal Society of Pathologists (22). From the length of the sample and the number of 360 turns by the vessels, we calculated the umbilical coiling index (UCI), with the standard normal value of one. In addition, with two scalpels fixed in the distance of two cm, three sections of the cord were cut. We stained their ends with ink and made prints on a millimeter paper, allowing them to be pushed to the paper by their natural weight. All the samples were handled by the same person. The area of the cross-sectional surface was measured using Image J 1.47v (2013) computer software on 3x6 prints in each case.

For the preparation and evaluation of the histological sections of the samples, we used the remaining cord and placental tissue. These data fundamentally determined the subsequent evaluation of the results. Two-way ANOVA statistical analysis was performed via Prism 6 (c 1992-2012 GraphPad Software Inc.).

## Results

All together 27 placentas and cords (22 control and 5 GDM) were examined. The mean age of the pregnant women in the control group was 32.09 ( $\pm 5.66$  SD) versus 34.20 ( $\pm 4.97$  SD) in the GDM group. The number of previous gestations was 1.46 in the control and 2.8 in the GDM group. We recorded two previous intrauterine growth restricted newborns in the diabetic group, and one macrosomic newborn in the control group. Pregnancy has long been known to be diabetogenic in the sense of the progressive metabolic changes. Proportional regression analysis revealed that the relative risk of developing non-insulin-dependent diabetes mellitus postpartum was 1.95 (95% CI, 1.63-2.33) for each 4.5 kg of weight gained during follow-up (23).

In the control group, medications taken during pregnancy were either one of the available over-the-counter pregnancy multivitamins or none at all. In the GDM group, methyldopa, magnesium, vitamin B6, verapamil-hydrochloride, calcium-dobezilat and multivitamins were taken none month prior to giving birth. The clinical data of the pregnant women and their newborns are summarized in Table 1.

All three vessels were present in each case along the entire length of the three to seven days old formalin-fixed samples. The pathomorphological data are shown in Table 2. The coiling of the cords is typically counterclockwise, twisted to the left, but twisting to the right occurred in 4 cases too; in the healthy control group (n = 3) and in the GDM group (n = 1). The UCI was calculated as the number of full turns made by the vessels within five centimeters. Perivascular hematoma and one hemangioma cavernosum were observed in the control, while two cases of multiple false

knots, a slight funisitis and edematous cord were found in the GDM group. True knots, abnormal vascular division, stenosis, stricture, meconium staining, maceration, thrombosis, calcification around the vessels, or other differences, discoloration, or odor were not observed. The cross-sectional surface area of the formalin-fixed tissue was compared to the measurements made on the ultrasonographic images. The cross-sectional surface area of the GDM fetuses' umbilical cords is roughly 65% of control cords measured in utero, and 76% after formalin fixation. The mean cord cross-sectional areas measured by 2D ultrasound were 344.00 mm<sup>2</sup> ( $\pm 0.46$  SD) in the control group and 224.50 mm<sup>2</sup> ( $\pm 0.74$  SD) in the diabetic group ( $p < 0.05$ ). After formalin fixation for three to seven days the cross-sectional areas were 124.00 mm<sup>2</sup> ( $\pm 35.47$  SD) and 93.75 mm<sup>2</sup> ( $\pm 9.86$  SD) respectively ( $p < 0.05$ ).

Measured with the ultrasonographic VOCAL technique, we found that the mean FI was 34.45% ( $\pm 4.59$  SD) in the control group and 29.80% ( $\pm 3.68$  SD) in the GDM group (ns); the mean VI was 6.21% ( $\pm 2.69$  SD) and 3.5% ( $\pm 2.97$  SD) ( $p < 0.05$ ), and the mean VFI was 2.31% ( $\pm 1.23$  SD) and 0.95% ( $\pm 1.20$  SD) (ns) respectively. The mean value of the umbilical artery S/D was 2.27 ( $\pm 0.22$  SD) in controls and 2.18 ( $\pm 0.45$  SD) ( $p < 0.05$ ) in diabetic pregnancies.

Oxytocin did not elicit significant change in the vascular tone in the arteries and the veins, and the responsiveness of the vessels was not different significantly in the two groups (Figure 1). Desmopressin was also added to the vessels in logarithmic noncumulative concentrations (24) as shown in Figure 2, but there was again no response.

## Discussion

In our study, umbilical 3D ultrasound examination showed that, compared to their gestational age, GDM fetuses have the normal S/D velocity curve. The VI is lower than in normal pregnancies because the development of blood vessels is not proportional to the growth of the placenta. In addition, they are damaged by the high serum glucose level. The

**Table 1.** Clinical and biometric data of the pregnant and newborns.

	Control (n=22)			GDM (n=5)			p
	Mean	SD	SEM	Mean	SD	SEM	
BMI before pregnancy	21.68	3.18	1.20	24.42	5.58	2.79	0.3968
BMI after pregnancy	25.85	1.85	0.58	30.83	4.44	1.98	0.0425*
previous pregnancies	1.46	1.97	0.59	2.80	0.84	0.37	0.0226*
systolic blood pressure (Hgmm)	123.20	25.86	7.80	124.00	19.49	8.72	0.9185
diastolic blood pressure (Hgmm)	78.00	10.63	3.21	83.00	13.04	5.83	0.4395
gestational age (weeks)	39.20	1.23	0.39	38.22	2.54	0.85	0.2812
1 minute Apgar	9.46	0.52	0.16	8.20	1.1	0.49	0.0213*
5 minute Apgar	10.00	0.00	0.00	9.00	1.23	0.55	0.1419
Rohner's ponderal index	2.69	0.25	0.08	2.85	0.35	0.16	0.1867
BMI of newborn	13.16	0.96	0.32	14.10	1.99	0.89	0.3518
weight (g)	3221	266.1	94.08	3627	363.5	148.40	0.0411*
AC (mm)	290.5	34.65	24.50	383.80	29.26	14.63	0.6981
HC (mm)	303.50	9.19	6.50	318.50	16.30	8.15	0.1533
AC/HC	1.04	0.07	0.04	1.28	0.08	0.04	0.1238
BPD (mm)	88.00	4.69	2.34	92.50	3.78	2.18	0.1750
FOD (mm)	109.50	5.92	3.42	115.00	9.01	4.50	0.3458
FL (mm)	65.50	6.61	3.30	73.00	4.00	2.31	0.0832
FL/BPD	0.74	0.07	0.04	0.79	0.03	0.02	0.0980
BMI before pregnancy	21.68	3.18	1.20	24.42	5.58	2.79	0.3968

\*p&lt;0.05

BMI= body mass index, AC= abdominal circumference, HC= head circumference, BPD= biparietal diameter, FOD= frontooccipital diameter, FL= femur length.

increased entry of glucose into vascular smooth muscle cells via GLUT1 transporter mediated by IL1 $\beta$  activates the pentose phosphate pathway, thus permitting some of the excess glucose to be metabolized via this route. This in turn led to an over activation NADPH oxidase, resulting in increased generation of free radicals and the

subsequent downstream proinflammatory signaling. Free radicals, inflammation and oxidative stress lead to atherosclerosis (25).

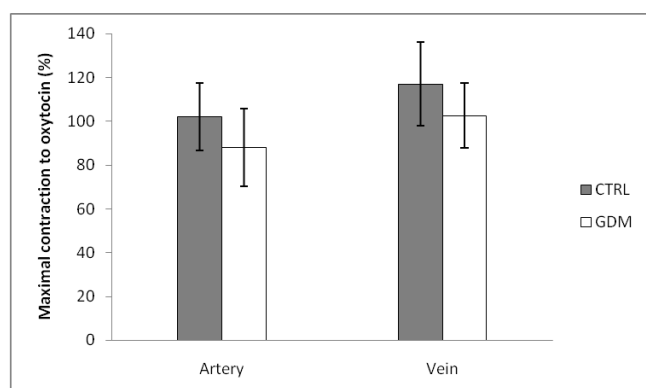
The uteroplacental circulation can be detected by the flowmetry of the umbilical and uterine arteries. The wave and shape of the flow, both in umbilical and uterine arteries, depends on the

Southeastern European Medical Journal, Vol 1, 2017.

**Table 2.** The pathomorphological and histopathologic data of the samples.

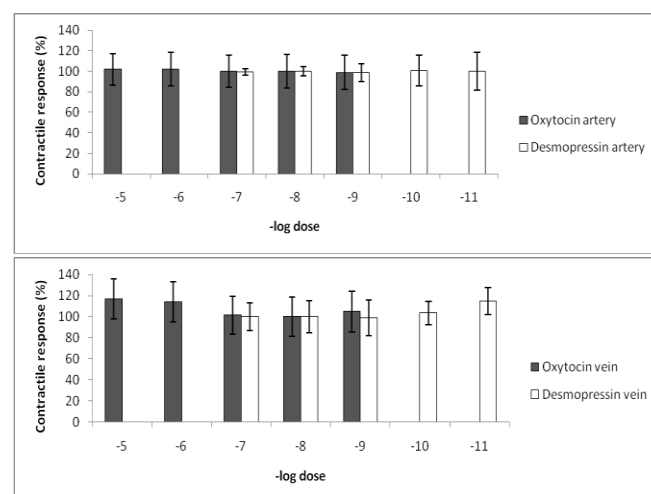
	Control (n=22)			GDM (n=5)			p
	Mean	SD	SEM	Mean	SD	SEM	
cord cross-sectional area (mm <sup>2</sup> )	124.00	35.47	11.22	93.75	9.86	4.41	0.0027*
cord length (cm)	58.00	9.15	2.89	59.60	7.13	3.19	0.6400
placental weight (g)	463.80	56.77	17.12	535.40	78.53	35.12	0.1083
fetal weight/placental weight	7.38	0.76	0.23	6.29	0.56	0.25	0.0134*
placenta thickness (mm)	27.73	4.10	1.24	28.00	4.47	2.00	0.8880
placenta longest diameter (mm)	160.90	13.75	4.15	164.00	5.48	2.45	0.1778
placenta shortest diameter (mm)	139.10	17.00	5.13	158.00	8.37	3.74	0.0071
umbilical coiling index (UCI)	1.43	0.77	0.25	2.00	1.00	0.45	0.0891

\*p&lt;0.05

**Figure 1.** Maximum change in vascular tone after oxytocin dosage.

Although the mean value for the case group is lower, the difference was not significant;  $p=0.208$  in case of the arteries and  $p=0.396$  in case of the veins. CTRL= control group, GDM= gestational diabetic group.

resistance in placental circulation. In diabetes, the increased blood flow resistance of the umbilical artery is just a late pathognomic sign of ischemic vascular changes in the placenta related to a direct ischemic effect on vascularization. These ischemic-hypoxic alterations can be seen in histopathological samples as syncytial nodes, hypervascularized villi and excessive interstitial calcification (26). We would like to emphasize the importance

**Figure 2.** Vascular tone after oxytocin and desmopressin dosage

We considered the spontaneously developing basal tone as 100%.24

of the placental-umbilical cord unit in pathologic pregnancies.

According to our results, the umbilical cord in the case of a gestational diabetic patient can be described as a thin cord with normal length, hypercoiled or normally coiled rope-like vessels. The incidence of multiple false knots is higher, and they rather tend to have a marginal placental insertion.

On the placental perfusion model, introducing vasopressin to the maternal side (30pg/ml-60 000pg/ml) and increasing the dosage until the vasopressin reaches its maximum concentration on the fetal side, they received 3110 pg/ml as the maximal agent transported through the placenta. This concentration is equivalent with  $5.74 \times 10^{-9} \text{M}$ , while our highest concentration was  $10^{-7} \text{M}$ . This suggests that treating pregnant women with vasopressin would not influence the fetoplacental circulation. Vasopressin or oxytocin concentration still can be increased in vivo by fetal production (27).

As described by Holcberg G., et.al (2002) oxytocin does have a vasoactive effect on meconium impregnated placentas, but no effect on normal placentas. Maternal oxytocin can pass through the placenta and reach the fetal brain, and induce the hyperpolarization of GABAergic neurons in the fetal hippocampus and neocortex during delivery. Reduction of GABA-mediated excitation induced by oxytocin has been demonstrated and completely eliminated by Atosiban. Since hypoxic brain damage is the leading cause of fetal death, the important conclusion is that oxytocin has an inhibitory cortical and hippocampal neuronal effect by which it reduces fetal brain oxygen and nutrient requirements, and therefore it is less sensitive to hypoxia (4). Therefore we assume that in cases of placentas without meconium impregnation, oxytocin does not bind to the receptors to elicit vasoconstriction in the placenta, and it can pass to the umbilical cord, where there is no active receptor. Thus, it can exert a greater hyperpolarization in the fetal brain. In term pregnancies during delivery, if there is an acute hypoxia, the oxytocin produced by the mother can protect the fetal brain. In contrast, it seems that in cases of the presence of meconium for several hours, it is important to note the increase of vascular tone in the placenta.

The macroscopic evaluation of the formalin fixed tissues showed that the volume had reduced, but the ratios between the control and case groups remained the same, so these data correlated with the clinical measurements. In cases of diabetic pregnancies, we found an increased umbilical coiling index (number of

$360^\circ$  turns within 5cm long segment at the placental end). The clinical aspect of the coiling pattern and coiling index is that a thin and hypocoiled cord is more vulnerable to strangulation, striction and other mechanical events. The thin cord that is not well-protected by Wharton's jelly is prone to striction and mechanical injuries too. There was no significant difference in the case of birth weight and placental weight either, but we did find significant difference in their ratios. The shortest diameter of the GDM placentas was significantly longer than the control ones, while there was no significant difference in the longer diameter or thickness measured at the cord insertion point. Therefore, we might observe the diabetic patients' placentas as more round and less oval shaped, heavier, and exhibiting a pale calcification.

We suppose that umbilical vessels have a unique receptor profile to regulate vascular tone though these vessels may injure easily because of mechanical insult. Regarding the importance of the umbilical vascular tone in fetal development, the investigation of the exact biochemical mechanisms could be crucial in the prevention of any developmental disturbances since the onset of gestational diabetes is within the time of pregnancy, resulting in a decreased possibility of awareness of the illness by the pregnant woman. By taking into consideration all the receptor changes of fetoplacental vascularization, we may be able to protect the fetus from an adverse outcome by specific treatment.

### Acknowledgements

This work did not receive funding.

### Competing interests

None to declare.

### References

1. Kim C, Newton KM, Knopp RH. Gestational Diabetes and the Incidence of Type 2 Diabetes: A systematic review. *Diabetes Care*. 2002; Oct, 25(10) 1862-



1868. <https://doi.org/10.2337/diacare.25.10.1862>
2. Kun A, Tornóczy J, Tabák AG. The prevalence and predictors of gestational diabetes in Hungary. *Horm Metab Res.* 2011;43(11):788-793. doi: 10.1055/s-0031-1287795
  3. Campos GM, Rabl C, Havel PJ, Rao M, Schwarz JM, Schambelan M, et al. Changes in Post-prandial Glucose and Pancreatic Hormones, and Steady-State Insulin and Free Fatty Acids after Gastric Bypass Surgery. *Surg Obes Relat Dis.* 2013;10(1):1-8. doi:10.1016/j.soard.2013.07.010.
  4. Keely E, Barbour LA. Management of Diabetes in Pregnancy. *Endotext* [Internet]. 2014 [cited 2017 May 03] Available from: <https://www.ncbi.nlm.nih.gov/books/NBK279010/>
  5. Sandler V, Reisseter AC, Bain JR, Muehlbauer MJ, Nodzanski M, Stevens RD, Ilkayeva O, Lowe LP, Metzger BE, Newgard CB, Scholtens DM, Lowe Jr WL. Associations of maternal BMI and insulin resistance with the maternal metabolome and newborn outcomes. *Diabetologia.* 2016;60(3):518-530. doi: 10.1007/s00125-016-4182-2.
  6. HAPO Study Cooperative Research Group. Hyperglycaemia and Adverse Pregnancy Outcome (HAPO) Study: associations with maternal body mass index. *BJOG.* 2010;117(5):575-584. doi: 10.1111/j.1471-0528.2009.02486
  7. Reece EA, Leguizamón G, Wiznitzer A. Gestational diabetes: the need for a common ground. *Lancet.* 2009;373(9677):1789-1797. doi: 10.1016/S0140-6736(09)60515-8
  8. Holcberg G, Sapir O, Huleihel M, Triger M, Lazer S, Katz M, Mazor M, Schneider H. Vasoconstrictive activity of oxytocin in meconium impregnated human placentas. *Eur. J. Obstet. Gynecol Reprod Biol.* 2002;101(2):139-142.
  9. Wing DA, Goharkhay N, Felix JC, Rostamkhani M, Naidu YM, Kovacs BW. Expression of the Oxytocin and V1a Vasopressin Receptors in Human Myometrium in Differing Physiologic States and following Misoprostol Administration. *Gynecol Obstet Invest* 2006;62(4):181-185.
  10. Arrowsmith S, Wray S. Oxytocin: its mechanism of action and receptor signaling in the myometrium. *J Neuroendocrinol.* 2014;26(6):356-369. doi: 10.1111/jne.12154
  11. Koukoulas I, Risvanis J, Douglas-Denton R, Burrell LM, Moritz KM, Wintour EM. Vasopressin Receptor Expression in the Placenta. *Biol Reprod.* 2003;69(2):679-686.
  12. Thibonnier M, Conarty DM, Preston JA, Plesnicher CL, Dweik RA, Erzurum SC. Human Vascular Endothelial Cells Express Oxytocin Receptors. *Endocrinology.* 1999;140(3):1301-1309.
  13. Kaufmann JE, Oksche A, Wollheim CB, Günther G, Rosenthal W, Vischer UM. Vasopressin-induced von Willebrand factor secretion from endothelial cells involves V2 receptors and cAMP. *J Clin Invest.* 2000;106(1):107-116.
  14. Kaufmann JE, Iezzi M, Vischer UM. Desmopressin (DDAVP) induces NO production in human endothelial cells via V2 receptor. and cAMP-mediated signaling. *J Thromb Homeost.* 2003;1(4):821-828.
  15. WHO. Diagnostic Criteria and Classification of Hyperglycaemia First Detected in Pregnancy. WHO Guidelines Approved by the Guidelines Review Committee [Internet]. 2013 [cited 2017 May 4] Available from: [http://apps.who.int/iris/bitstream/10665/85975/1/WHO\\_NMH\\_MND\\_13.2\\_eng.pdf](http://apps.who.int/iris/bitstream/10665/85975/1/WHO_NMH_MND_13.2_eng.pdf)
  16. Hadlock FP, Harrist RB, Sharman RS, Deter RL, Park SK. Estimation of fetal weight with the use of head, body and femur measurements: a prospective study. *Am J Obstet Gynecol.* 1985;151(3):333-337.
  17. Pretorius DH, Nelson TR, Baergen RN, Pai E, Cantrell C. Imaging of placental vasculature

- using three-dimensional ultrasound and color power Doppler: a preliminary study. *Ultrasound Obstet Gynecol.* 1998;12(1): 45-49.
18. Mercé LT, Barco MJ, Bau S, Kupesic S, Kurjak A. Assessment of placental vascularisation by three-dimensional power Doppler "Vascular Biopsy" in normal pregnancies. *Croat Med J.* 2005;46(5):765-771.
  19. Tuuli MG, Houser M, Odibo L, Huster K, Macones GA, Obido AO. Validation of placental vascular sonobiopsy for obtaining representative placental vascular indices by three-dimensional power Doppler ultrasonography. *Placenta.* 2010 ;31(3): 192-196. doi: 10.1016/j.placenta.2009.12.018
  20. Csákány MG. Ultrasonographic Diagnosis of Fetal Growth Disturbances. In: Tóth Z, Papp Z, editors. *Diagnostic Ultrasonography in Obstetrics and Gynaecology.* 2nd edition. Budapest: White Golden Books Kft; 2006. p.325-332
  21. Romani F, Lanzone A, Tropea A, Tiberi F, Catino S, Apa R. Nicotine and cotinine affect the release of vasoactive factors by trophoblast cells and human umbilical vein endothelial cells. *Placenta.* 2010 ;32(2):153-160. doi: 10.1016/j.placenta.2010.11.010
  22. Cox P, Evans C. Tissue pathway for histopathological examination of the placenta. Royal College of Pathologists [internet]. 2011 [Cited: 2017. May 4] Available from: [http://www.rcpath.org/Resources/RCPPath/Migrated%20Resources/Documents/G/G108\\_TPplacenta\\_Sept11.pdf](http://www.rcpath.org/Resources/RCPPath/Migrated%20Resources/Documents/G/G108_TPplacenta_Sept11.pdf)
  23. Peters RK, Kjos SL, Xiang A, Buchanan TA. Long-term diabetogenic effect of single pregnancy in women with previous gestational diabetes mellitus. *Lancet.* 1996;347(8996): 227-30.
  24. Jakó M, Surányi A, Kaiser L, Domokos D, Gáspár R, Bártfai G. Pathophysiological changes of umbilical vessels in intrauterine growth restriction. *Orv Hetil.* 2014 ; 155(50):1989-1995. doi: 10.1556/OH.2014.30003.
  25. Peiró C, Romacho T, Azcutia V, Villalobos L, Fernández E, Bolaños JP, et al. Inflammation, glucose, and vascular cell damage: the role of the pentose phosphate pathway. *Cardiovasc Diabetol.* 2016;15:82. doi: 10.1186/s12933-016-0397-2
  26. Akarsu S, Bagirzade M, Omeroglu S, Büke B. Placental vascularization and apoptosis in Type-1 and gestational DM. *J Matern Fetal Neonatal Med* 2016;30(9):1045-1050. doi: 10.1080/14767058.2016.1199676
  27. Ray JG, Boskovic R, Knie B, Hard M, Portnoi G, Koren G. In vitro analysis of human transport of desmopressin. *Clin Biochem.* 2004;37(1):10-13.